










Case Report

An MR Imaging Study of Communicating Hydrocephalus After Gamma Knife Radiosurgery for Vestibular Schwannoma

Endalkachew Belayneh Melese¹ , **Haitham Alhussain²** , **Fekadu Belay Ayalew¹** , **Nathnael Abera Woldehana¹** , **Motuma Gonfa Ayana³** , **Simon Tsegaye Geleta³** , **Ruth Betremariam Abebe³** , **Abrham Workineh Azale⁴** , **Wondimagegn Tibebu Tilahun^{3,*}** 

¹Johns Hopkins Bloomberg School of Public Health, Johns Hopkins University, Baltimore, Maryland, United States of America

²Department of Public Health and Infection Control, King Fahad Hospital, Alhofuf, Saudi Arabia

³Department of Internal Medicine, University of Gondar, Addis Ababa, Ethiopia

⁴Department of Internal Medicine, Tikur Anbessa Specialized Hospital, Addis Ababa, Ethiopia

Abstract

Patients with vestibular schwannoma (VS) face a 3.7-23.7% risk developing hydrocephalus. Small-sized VS are associated with communicating or non-communicating hydrocephalus. Hydrocephalus in VS patients can persist or worsen post-tumor removal. Gamma knife radiosurgery is effective, especially in younger patients with functional hearing. Although the causal relationship between gamma knife radiosurgery and hydrocephalus isn't firmly established, this case reports a possible association between developing hydrocephalus and Vestibular schwannoma. Elevated CSF protein suggests communicating hydrocephalus due to tumor necrosis. The rarity of hydrocephalus post-gamma knife surgery likely relates to tumor variations rather than procedural nuances. Gamma Knife radiosurgery for vestibular schwannomas can lead to communicative hydrocephalus. MR imaging, including pre- and post-treatment scans, along with MR CSF cine-flow studies, highlights the link between gamma knife involvement and hydrocephalus development. Despite the rarity, this negative outcome underscores the need for careful consideration and investigation of risk factors associated with hydrocephalus post-radiosurgery. A middle aged man with vestibular schwannoma was investigated in this case. Patient was procedure through gamma knife radiosurgery for vestibular schwannoma. Patient was passed through MR scans before the radio surgical procedure and 9 months past surgical procedure. Nine months later, severe ventriculomegaly was observed, revealing central necrosis in the tumor. Lumbar puncture indicated abnormal CSF characteristics without evidence of infection. Despite a failed endoscopic third ventriculostomy, MR imaging cine-flow studies confirmed free CSF flow, emphasizing the complexity of managing hydrocephalus post-gamma knife radiosurgery for vestibular schwannomas. VS typically occurs in older individuals, this case's younger age and optimal tumor size for gamma knife treatment add complexity. Faster-growing and larger tumors are more prone to post-treatment necrosis and hydrocephalus, necessitating careful management. MR cine-flow aids in hydrocephalus differentiation.

*Corresponding author: Wodett12@gmail.com (Wondimagegn Tibebu Tilahun)

Received: 27 January 2024; **Accepted:** 12 February 2024; **Published:** 29 February 2024



Copyright: © The Author(s), 2024. Published by Science Publishing Group. This is an **Open Access** article, distributed under the terms of the Creative Commons Attribution 4.0 License (<http://creativecommons.org/licenses/by/4.0/>), which permits unrestricted use, distribution and reproduction in any medium, provided the original work is properly cited.

Keywords

Gamma Knife, Radiosurgery, Hydrocephalus, Schwannoma, MR Imaging

1. Introduction

Gamma knife radiosurgery (GKR) is a therapeutically choice procedure for schwannomas invading Vestibule in the bony labyrinth. hydrocephalus can occur after vestibular schwannoma therapy with a GKR, the cause-and-effect relationship is still unclear as tumors can produce hydrocephalus on their own. We report a peculiar case with MR imaging that shows communicative hydrocephalus following GKR for vestibular schwannoma (VS). The timeline of development of hydrocephalus after GKR indicates involvement of procedure under discussion. We investigated potential contributing consequences of hydrocephalus following radiation therapy. MR CSF cine-flow aided in assessing possibilities of hydrocephalus in this setting. Communicating Hydrocephalus is both rare, and cannot be positively attributed towards adopted radio surgical procedure for curing VS. Magnetic resonance imaging was utilized pre and post procedure, to rule out for possible association between radio surgical procedure and incurred Schwannoma. Furthermore, MR CSF cine-flow investigation were included to efficiently manage vestibular schwannoma. The conclusive evidence possibly indicated that GKR post tumor necrosis was causing communicating hydrocephalus. GKR probably accelerated or instigated communicating hydrocephalus after gamma knife radio surgical procedure.

2. Case Report

An extensive record of impaired hearing and left-sided tinnitus was found in a 30-year-old man with a previously healthy record. An MR imaging investigation revealed a 3-cm enhancing mass connected to the left vestibular nerve. The patient, who had a third nerve palsy, bilateral 2+ papilledema, and headaches, decided against surgical removal and underwent gamma knife radiosurgery (GKR) instead. Thirty-seven weeks later, severe ventriculomegaly was found, with enlarged ventricles and no evidence of intraventricular CSF flow blockage. A 3-cm vestibular schwannoma (VS) was observed, with decreased internal enhancement, indicating central necrosis, after puncturing lumbar region, the CSF exhibited very few red blood cells and a protein level of 132 mg/dL. Glucose levels were 61 mg/dL, and white blood cell counts were slightly higher at 17/mm³. Infection was not observed as well as Gram smear and culture were negative. An MR imaging cine-flow study verified that CSF was flowing freely and that there was no intraventricular obstruction. Endoscopic third ventriculostomy was performed, but no impact was found.

3. Discussion

Patients with vestibular schwannoma (VS), are at risk of developing hydrocephalus between 3.7-23.7 though in some smaller series studies it ranges up to 42% [1, 2]. In larger VS, obstructive hydrocephalus is common while communicating or non-communicating HCP are associated with small sized VS. [2]. Endoscopic third ventriculostomy is gold standard procedure for treating obstructive non-communicative hydrocephalus, which makes it inapplicable to our patient [4]. Patients with VS, removal of tumor cannot stop hydrocephalus from its progression or further worsening. gamma knife radiosurgery is an effective approach towards tumor controlling patients with younger ages less than 40 years, and with functional hearing [5-7]. Development or possible exacerbation of hydrocephalus after gamma knife radio surgical procedure is evident from this case report. Albeit causal relationship between incidence of hydrocephalus in association with procedure is not well established yet the timeline of incidence of hydrocephalus tallies with other cases reported earlier declaring same association [8-10]. in majority of VS associated hydrophiles developed within one and half year [11, 12]. Patient has elevated CSF protein in accordance with the proposition that communicating hydrocephalus associated with vestibular schwannoma caused by tumor necrosis [13]. Consequently, CSF resorption is obstructed at the level of arachnoid granulations. These complications are associated with acoustic schwannoma but radiosurgery can possibly aggravate patient's condition. The rare occurrence of hydrocephalus following a gamma knife surgery most likely indicates small variations in the tumor rather than variations in radio surgical technique. It is established that VS have varied growth rates [14, 15]. The case understudy is different in two aspects, age of patient and tumor size. The size of tumor is optimal for gamma knife radiosurgery but the age of patient is somehow lesser than expected age for occurrence of acoustic schwannoma. the incidence of VS is frequent in the age range 65-74 years [16]. the growth of tumors is associated with age while the difference in sex is not an important factor in the incidence of vestibular schwannoma [17]. Although female patients can be suffered more by associated symptoms including tinnitus, vertigo and dizziness [18, 19]. Tumors with faster growth rates and greater sizes are more prone to develop posttreatment tumor necrosis and hydrocephalus. Although VS are slow growing tumor but changes to faster growth after the surgical treatment. Because of the elevated intracranial pressure, this frequently makes surgery challenging and necessitates further care post tumor removal. MR sine aided in

differentiating between non-communicating and communicating hydrocephalus.

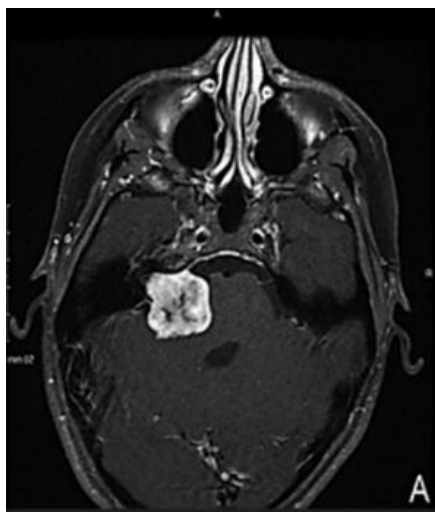


Figure 1. 14 days pre-procedure T1-weighted MR imaging.

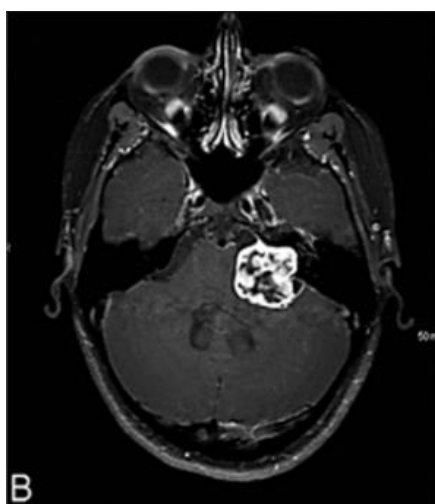


Figure 2. 36 weeks post procedure MR Image: Post treatment tumour exhibits central necrosis.

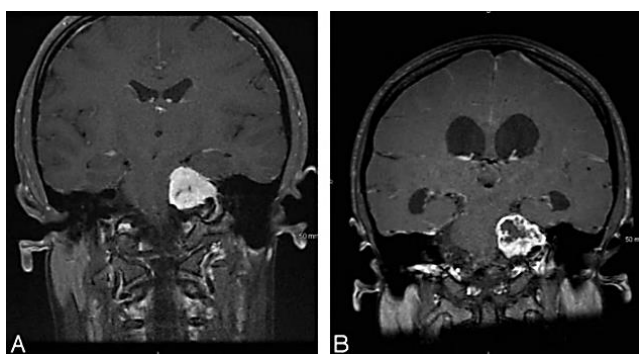


Figure 3. T1-weighted MR imaging after gadolinium (A) 14 days before and (B) 36 weeks post procedure image.

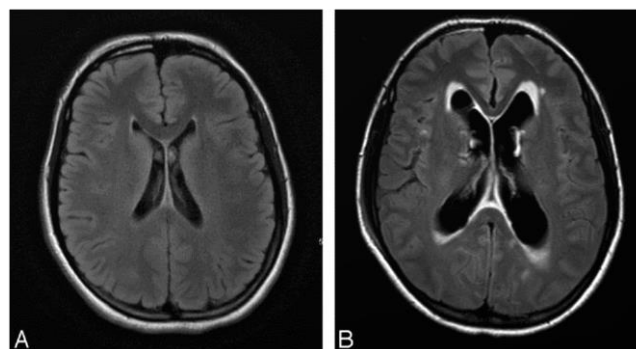


Figure 4. Axial fluid-attenuated inversion recovery MR images (A) 14 days before GKR (B) 36 Weeks post-GKR image. Ventriculomegaly is extended to third and fourth ventricle. Flow of CSF across ependymal layer of cells is shown in Figure 4B.

4. Conclusion

Our study was based on MR imaging of communicating hydrocephalus associated with vestibular schwannoma. Patient was treated with gamma knife radiosurgery for acoustic schwannoma but developed hydrocephalus possibly linked with treatment method. MR Sine flow provided guidance on the management of communicating hydrocephalus.

Acknowledgments

Study was and case report was led by Wondimagegn Tibebu Tilahun and Endalkachew contributed to the initial management of patient, conception of case report, data collection, literature review and writing of first draft by Haitham Alhussain. Nathnael Abera Woldehana and Motuma Gonfa Ayana contributed to literature review and critical revision of manuscript. Simon Tsegaye Geleta contributed to literature review and review of manuscript. contributed to literature review and revision of manuscript. Ruth Betremariam Abebe and Abraham Workneh Azale contributed to management of the patient, did the echocardiography and contributed to data collection, critical revision of the manuscript. All authors read and approved the final manuscript.

Abbreviations

GKR: Gamma Knife Radiosurgery
VS: Vestibular Schwannoma
CSF: Cerebrospinal Fluid
HCP: Hydrocephalus
MR Image: Magnetic Resonance Imaging

Conflicts of Interest

The authors declare no conflicts of interest.

References

- [1] Shin, D. A.-O., et al., Treatment Outcome of Hydrocephalus Associated with Vestibular Schwannoma. (1738-6586 (Print)).
- [2] Al Hinai, Q., et al., Communicating hydrocephalus and vestibular schwannomas: etiology, treatment, and long-term follow-up. (2193-6331 (Print)).
- [3] Yadav, Y. R., et al., Endoscopic third ventriculostomy. *J Neurosci Rural Pract*, 2012. 3(2): p. 163-73.
- [4] Boari, N., et al., Gamma Knife radiosurgery for vestibular schwannoma: clinical results at long-term follow-up in a series of 379 patients. (1933-0693 (Electronic)).
- [5] Flickinger, J. C., et al., Results of acoustic neuroma radiosurgery: an analysis of 5 years' experience using current methods. (0022-3085 (Print)).
- [6] Morelli, D., et al., Persistent hydrocephalus after early surgical management of posterior fossa tumors in children: is routine preoperative endoscopic third ventriculostomy justified? (0022-3085 (Print)).
- [7] Pirouzmand, F., J. Tator Ch Fau - Rutka, and J. Rutka, Management of hydrocephalus associated with vestibular schwannoma and other cerebellopontine angle tumors. (0148-396X (Print)).
- [8] Prabhuraj, A. R., et al., Hydrocephalus Associated with Large Vestibular Schwannoma: Management Options and Factors Predicting Requirement of Cerebrospinal Fluid Diversion after Primary Surgery. *Journal of neurosciences in rural practice*. 8(Suppl 1): p. S27-S32.
- [9] Kim, J., et al., Communicating Hydrocephalus Following Treatment of Cerebellopontine Angle Tumors. *World neurosurgery*. 165: p. e505-e511.
- [10] Thomsen, J., S. E. Tos M Fau - Børjesen, and S. E. Børjesen, Gamma knife: hydrocephalus as a complication of stereotactic radiosurgical treatment of an acoustic neuroma. (0192-9763 (Print)).
- [11] Linskey, M. E., et al., Stereotactic radiosurgery for acoustic tumors. (1042-3680 (Print)).
- [12] Gardner Wj Fau - Spittler, D. K., C. Spittler Dk Fau - Whitten, and C. Whitten, Increased intracranial pressure caused by increased protein content in the cerebrospinal fluid; an explanation of papilledema in certain cases of small intracranial and intraspinal tumors, and in the Guillain-Barre syndrome. (0028-4793 (Print)).
- [13] Rosenberg, S. I., Natural history of acoustic neuromas. (0023-852X (Print)).
- [14] van Leeuwen, J. P., et al., Acoustic neuroma: correlation among tumor size, symptoms, and patient age. (0023-852X (Print)).
- [15] Cioffi, G., et al., Epidemiology of vestibular schwannoma in the United States, 2004-2016. (2632-2498 (Electronic)).
- [16] Reznitsky, M., et al., Epidemiology and Diagnostic Characteristics of Vestibular Schwannomas-Does Gender Matter? (1537-4505 (Electronic)).
- [17] Vorasubin, N., et al., Factors That Affect Length of Hospital Stay After Vestibular Schwannoma Surgery. (1537-4505 (Electronic)).
- [18] Rosahl, S., et al., Diagnostics and therapy of vestibular schwannomas - an interdisciplinary challenge. (1865-1011 (Print)).
- [19] Hwang, S.-K., et al., Aggressive Vestibular Schwannomas with Postoperative Rapid Growth: Clinicopathological Analysis of 15 Cases. *Neurosurgery*, 2002. 51(6): p. 1381-1391.